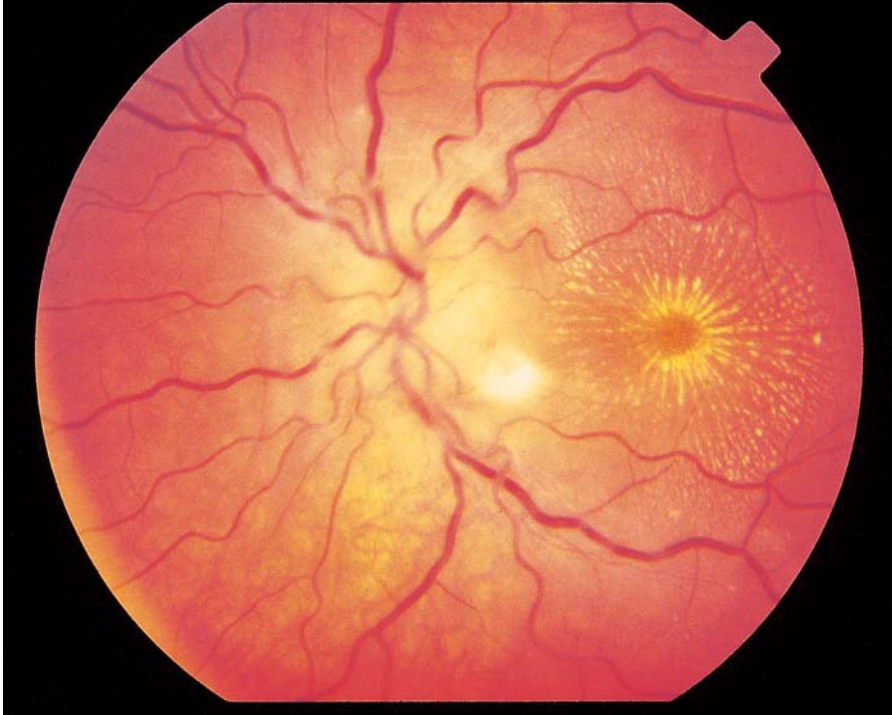


Optic Neuritis Due to *Bartonella henselae* Infection

A 14-YEAR-OLD GIRL PRESENTED WITH WORSENING HEADACHES, UNILATERAL decreased visual acuity (20/20 in the right eye and 5/200 in the left eye), and ocular pain in the left eye. The results of a neurologic examination were unremarkable. Contrast-enhanced computed tomography of the head and a lumbar puncture showed no abnormalities. A retinal examination showed bilateral optic-disk elevation with edema, lipid exudates that formed a macular star, and an area of choroiditis surrounded by serous fluid. The results of serologic evaluation for syphilis and Lyme disease and of a skin test for tuberculosis were negative. Indirect immunofluorescence assays showed that the titers of antibodies against *Bartonella henselae* were 1:160 or more for IgM and 1:512 or more for IgG. This constellation of findings has been called Leber's idiopathic stellate neuroretinitis, according to a description by Theodor Leber in 1916. Modern serodiagnostic testing has shown that in many cases the findings are due to *B. henselae*, the gram-negative bacterium that causes cat scratch disease. The patient owned a cat but did not recall a specific scratch.

Pharmacologic treatment of optic neuritis due to *B. henselae* infection in immunocompetent hosts is of uncertain value; the symptoms can resolve spontaneously, and controlled studies are lacking. Nonetheless, our patient was treated with prednisone and azithromycin. Six months later, the lipid exudates in the macula had been reabsorbed, and normal vision (20/20 in the right eye and 20/25 in the left eye) had returned.

Copyright © 2004 Massachusetts Medical Society.

Arnd M. Herz, M.D.
J. Michael Lahey, M.D.

Permanente Medical Group
Hayward, CA 94545