

ORIGINAL ARTICLE

Treatment of Early Childhood Medulloblastoma by Postoperative Chemotherapy Alone

Stefan Rutkowski, M.D., Udo Bode, M.D., Frank Deinlein, M.D.,
Holger Ottensmeier, Ph.D., Monika Warmuth-Metz, M.D., Niels Soerensen, M.D.,
Norbert Graf, M.D., Angela Emser, Dipl.Math., Torsten Pietsch, M.D.,
Johannes E.A. Wolff, M.D., Rolf D. Kortmann, M.D.,
and Joachim Kuehl, M.D.*†

ABSTRACT

BACKGROUND

From the Department of Pediatric Oncology, Children's Hospital (S.R., F.D., H.O., J.K.), and the Departments of Neuroradiology (M.W.-M.) and Pediatric Neurosurgery (N.S.), University of Würzburg, Würzburg; the Department of Pediatric Oncology, Children's Hospital (U.B.) and National Reference Center for Brain Tumors, Department of Neuropathology (T.P.), University of Bonn, Bonn; the Department of Pediatric Oncology, Children's Hospital, University of Homburg/Saar, Homburg/Saar (N.G.); Institute for Medical Statistics, Epidemiology, and Informatics, University of Mainz, Mainz (A.E.); the Department of Pediatric Oncology, Children's Hospital, University of Regensburg, Regensburg (J.E.A.W.); and the Department of Radiotherapy, University of Leipzig, Leipzig (R.D.K.) — all in Germany. Address reprint requests to Dr. Rutkowski at the Department of Pediatric Oncology, Children's Hospital, University of Würzburg, Josef-Schneider-Str. 2, D-97080 Würzburg, Germany, or at rutkowski@mail.uni-wuerzburg.de.

The prognosis for young children with medulloblastoma is poor, and survivors are at high risk for cognitive deficits. We conducted a trial of the treatment of this brain tumor by intensive postoperative chemotherapy alone.

METHODS

After surgery, children received three cycles of intravenous chemotherapy (cyclophosphamide, vincristine, methotrexate, carboplatin, and etoposide) and intraventricular methotrexate. Treatment was terminated if a complete remission was achieved. Leukoencephalopathy and cognitive deficits were evaluated.

RESULTS

Forty-three children were treated according to protocol. In children who had complete resection (17 patients), residual tumor (14), and macroscopic metastases (12), the five-year progression-free and overall survival rates (\pm SE) were 82 ± 9 percent and 93 ± 6 percent, 50 ± 13 percent and 56 ± 14 percent, and 33 ± 14 percent and 38 ± 15 percent, respectively. The rates in 31 patients without macroscopic metastases were 68 ± 8 percent and 77 ± 8 percent. Desmoplastic histology, metastatic disease, and an age younger than two years were independent prognostic factors for tumor relapse and survival. Treatment strategies at relapse were successful in 8 of 16 patients. There were no major instances of unexpected toxicity. In 19 of 23 children, asymptomatic leukoencephalopathy was detected by magnetic resonance imaging. After treatment, the mean IQ was significantly lower than that of healthy controls within the same age group but higher than that of patients in a previous trial who had received radiotherapy.

CONCLUSIONS

Postoperative chemotherapy alone is a promising treatment for medulloblastoma in young children without metastases.

*Deceased.

†A complete list of investigators is provided in the Appendix.

N Engl J Med 2005;352:978-86.
Copyright © 2005 Massachusetts Medical Society.

TWENTY-FIVE TO 35 PERCENT OF CASES of medulloblastoma, the most common malignant brain tumor of childhood, occur in children younger than three years of age.¹ In contrast to the prognosis for older children, the prognosis for infants and young children treated with surgery, radiotherapy, and chemotherapy remains poor: survival rates have been static for two decades.² The lack of progress relates not only to the frequent occurrence of metastases at diagnosis but also to the biology of medulloblastoma in young children.³⁻⁵ In addition, the susceptibility of the immature brain to radiotherapy-induced cognitive deficits,⁶⁻⁸ which increase for years after radiotherapy,^{9,10} has set age limitations on the use of radiotherapy in children. Some patients have been cured by postoperative chemotherapy alone,¹¹⁻¹⁴ but survival rates after chemotherapy, with or without radiotherapy, remain unsatisfactory at 25 to 45 percent.

A pilot trial showed that postoperative chemotherapy can delay the start of radiotherapy.¹⁵ In the present trial we investigated whether intensive postoperative chemotherapy alone improves survival and cognitive function in young children. Instead of radiotherapy, we administered intraventricular methotrexate through an implanted subcutaneous reservoir, with the aim of prolonging cytotoxic methotrexate levels in the cerebrospinal fluid by giving repeated small single doses.¹⁶ Patients underwent detailed neuropsychological testing and were monitored for leukoencephalopathy, which can be a toxic effect of methotrexate.¹⁷

METHODS

PATIENTS

From April 1992 through December 1997, we registered 62 children with medulloblastoma who were under three years of age. We excluded eight patients because they had a different histopathologi-

cal diagnosis in central review, eight because they had different chemotherapy or primary radiotherapy or both, and three because they had no therapy or were lost to follow-up. The remaining 43 patients (28 boys and 15 girls) were treated in 31 pediatric oncology centers. Informed consent was obtained from legal representatives of all patients.

SURGERY

The maximum possible surgical removal of the primary tumor, depending on the anatomical location of the tumor and the condition of the child, was recommended. The extent of resection was assessed by magnetic resonance imaging (MRI) or computed tomography (CT) performed within 72 hours after surgery. After histologic confirmation of the diagnosis, an intraventricular subcutaneous reservoir (an Ommaya or a Rickham reservoir) was implanted in the anterior horn of a lateral ventricle.

PATHOLOGICAL ANALYSIS

The diagnosis of medulloblastoma was histologically confirmed in all 43 patients by a central pathology laboratory. Tumors were classified according to the World Health Organization classification of brain tumors as classic medulloblastoma (23 patients) or desmoplastic medulloblastoma (20 patients). Other histologies (six atypical teratoid rhabdoid tumors, one ependymoblastoma, and one choroid-plexus carcinoma) were excluded. Cytospin preparations of lumbar cerebrospinal fluid were available from 29 patients for the analysis of tumor cells.

TREATMENT

Chemotherapy was started two to four weeks after surgery. Children received three two-month cycles of chemotherapy, each consisting of cyclophosphamide, methotrexate (followed by leucovorin rescue after 42 hours), vincristine, carboplatin, and etoposide (Table 1). Doses of cyclophosphamide,

Table 1. Chemotherapy Regimen.*

Week 1	Week 3	Week 5	Week 7
Methotrexate (2 mg/day, intraventricular), day 1-4	Methotrexate (2 mg/day, intraventricular), day 1-2	Methotrexate (2 mg/day, intraventricular), day 1-2	Methotrexate (2 mg/day, intraventricular), day 1-4
Cyclophosphamide (800 mg/m ² of body-surface area/day, intravenous), day 1-3	Methotrexate (5 g/m ² , intravenous), 24 hr	Methotrexate (5 g/m ² , intravenous), 24 hr	Carboplatin (200 mg/m ² , intravenous), day 1-3
Vincristine (1.5 mg/m ² , intravenous), day 1	Vincristine (1.5 mg/m ² , intravenous), day 1	Vincristine (1.5 mg/m ² , intravenous), day 1	Etoposide (150 mg/m ² , intravenous), day 1-3

* One two-month cycle of intraventricular and systemic chemotherapy consisted of four treatments. The second and third cycles of chemotherapy were started at weeks 10 and 19, respectively. Treatment was finished if patients were in complete remission after three cycles of chemotherapy.

vincristine, and carboplatin were adjusted for age (6 months of age or less, 66 percent of the full dose; 7 to 12 months of age, 80 percent). The patients also received 36 intraventricular doses of methotrexate. Treatment was stopped if patients had complete continuous remission after three cycles of chemotherapy. Otherwise, children received second surgery, radiotherapy, or experimental chemotherapy as deemed appropriate.

EVALUATION AND FOLLOW-UP

The presence of macroscopic solid or laminar metastases was evaluated by initial cranial and spinal MRI (with or without gadolinium) according to the tumor staging system of Chang and colleagues.¹⁸ In this system, stage M1 denotes disseminated tumor cells in the cerebrospinal fluid, stage M2 intracranial macroscopic solid or laminar metastases, and stage M3 spinal macroscopic solid or laminar metastases. Residual postoperative tumors were evaluated with MRI within 72 hours after surgery. Neurologic status was assessed before each cycle of chemotherapy. After each cycle, cranial MRI scans and audiograms were obtained, and children underwent spinal MRI and cytologic analysis of lumbar cerebrospinal fluid if initial staging revealed metastatic disease.

Complete response was defined as the total disappearance of residual tumors or macroscopic metastasis during chemotherapy or at the end of treatment. Partial response was defined as a decrease of at least 25 percent of the tumor size, stable disease as a decrease or increase of less than 25 percent,

and progressive disease as an increase of at least 25 percent.

Before each treatment, the complete blood count, electrolyte levels, and creatinine concentration were determined, and liver-function tests were performed. Serum concentrations of methotrexate were measured at standard intervals until levels were below 0.25 μmol per liter.

Intraventricular administration of methotrexate was omitted in patients with suspected infection of the central nervous system, thrombocytopenia (a platelet count of less than 30,000 per cubic millimeter), or evidence of disturbed circulation of cerebrospinal fluid. In patients with a ventriculo-peritoneal or ventriculoatrial shunt, intraventricular administration was permitted only in cases of metastatic disease. To determine the extent and course of leukoencephalopathy, cranial MRI findings obtained during and after treatment were classified independently by two reviewers according to the classification methods of Fazekas.¹⁹

After treatment, legal representatives of all surviving children were informed, and we requested permission to perform a neuropsychological examination. All children for whom consent was obtained underwent detailed age-adapted neuropsychological examination, performed by the same psychologist. The intelligence levels of patients were determined by the Colored Progressive Matrices test and the Kaufmann-Assessment Battery for Children. Sensorimotor abilities were measured by the Developmental Test of Visual-Motor Integration.

Table 2. Initial Stage, Extent of Resection of the Primary Tumor, and Response to Chemotherapy.*

Stage	Surgery		Response to Chemotherapy			Overall Response %
	Complete no. (%)	Incomplete	Complete	Partial	Stable or Progressive Disease no.	
M0/M1†	17 (40)	14 (33)	10	1	3	79
M2/M3†	6 (14)	6 (14)	2	3	7	42
Total	23 (53)	20 (47)	12	4	10	62

* Patients were categorized in three groups according to initial tumor stage: complete resection (17 patients) and incomplete resection (14 patients) without macroscopic metastases (stage M0 or M1), and macroscopic cranial or spinal metastases regardless of residual tumor, stage M2 or M3 (12 patients). Response to chemotherapy was assessable in 26 patients with postoperative residual tumors, metastases, or both. Patients with early response followed by progressive disease during chemotherapy were classified as not having a response. Because of rounding, percentages may not sum to the total.

† Dissemination of tumor cells into the cerebrospinal fluid was confirmed in samples from 9 of 29 patients.

STATISTICAL ANALYSIS

Survival was estimated by the Kaplan–Meier method, and the log-rank test was used for comparisons. For the univariate analysis, a local significance level of 5 percent was used (i.e., this significance level was assessed for each test separately). Plus–minus values are standard errors. A stepwise multivariate Cox regression analysis was used to analyze possible prognostic factors for the risk of recurrence or death (score test, $P \leq 0.05$ for inclusion criteria; likelihood-ratio test, $P \geq 0.10$ for exclusion criteria). The grade of leucoencephalopathy, the cumulative doses of intraventricular and intravenous methotrexate, and the doses of craniospinal irradiation were correlated with the use of the Spearman rank-correlation method. Results of intelligence tests are expressed as T scores (mean \pm SD), 50 ± 10) and were compared with the use of the Mann–Whitney U test.

RESULTS

STAGING

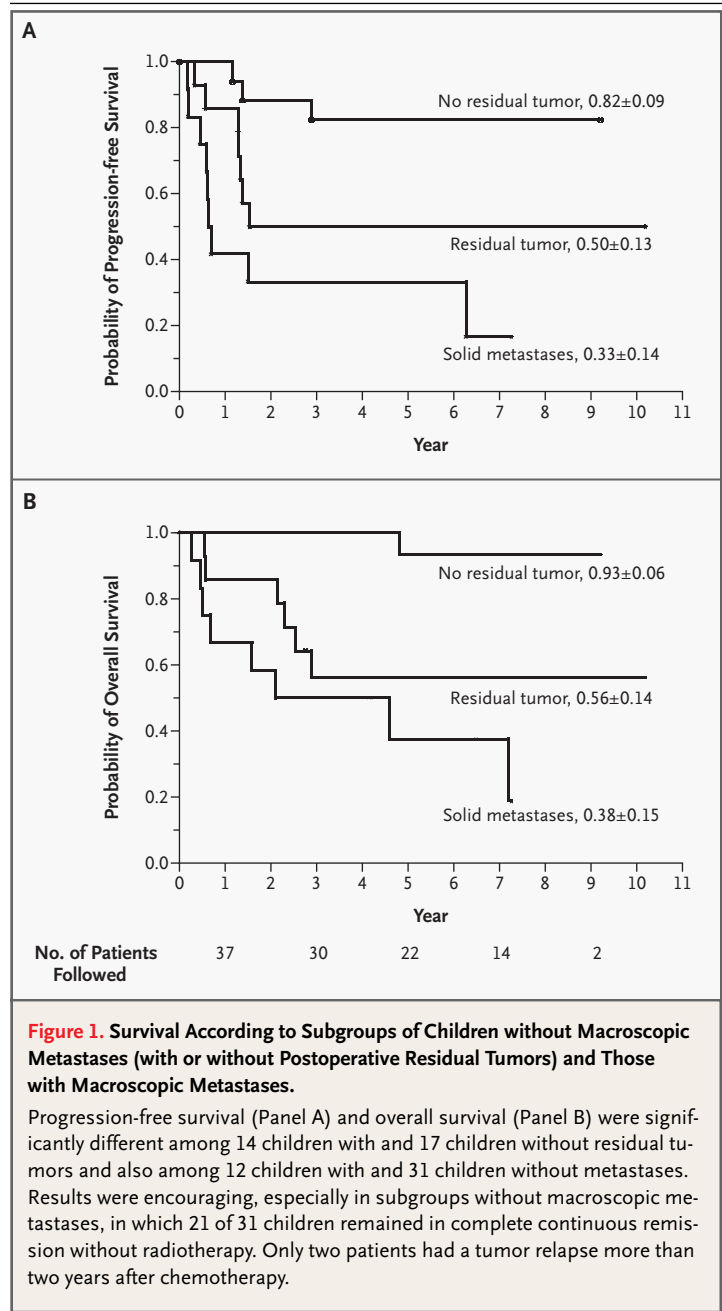
In 31 children (72 percent), no cranial (Chang stage M2+) or spinal (stage M3+) metastases were detectable at diagnosis. The remaining 12 children (28 percent) had macroscopic metastases (Table 2).

PROGRESSION-FREE AND OVERALL SURVIVAL

The estimated five-year progression-free and overall survival rates among the 43 children were 58 ± 9 percent and 66 ± 7 percent, respectively. In children who had complete resection, those who had residual tumor, and those who had stage M2 or M3 metastatic disease, the five-year progression-free and overall survival rates were 82 ± 9 percent and 93 ± 6 percent, 50 ± 13 percent and 56 ± 14 percent, and 33 ± 14 percent and 38 ± 15 percent, respectively (Fig. 1). The median follow-up times of surviving patients in these three groups were 7.1 years (range, 3.6 to 9.2), 6.1 years (2.7 to 10.2), and 5.5 years (4.2 to 7.3), respectively. In 31 patients without macroscopic metastases, differences between groups with complete and incomplete surgical resection were significant for overall survival ($P=0.009$) and for progression-free survival ($P=0.04$). Of 17 children without residual postoperative tumor, 14 remained in complete continuous remission without radiotherapy. The five-year progression-free and overall survival rates among 31 patients without macroscopic metastases were 68 ± 8 percent and 77 ± 8 percent, and 21 of these 31 patients remain in continuous remission without radiotherapy. Differ-

ences between nonmetastatic and metastatic (stage M2 or M3) disease were significant ($P < 0.002$). Of 12 patients with initial macroscopic metastases, 3 achieved a continuous remission without radiotherapy.

Twenty patients with desmoplastic medulloblastoma had significantly better five-year progression-free and overall survival rates (85 ± 8 percent and 95 ± 5 percent) than did 23 patients with classic



medulloblastoma (34 ± 10 percent and 41 ± 11 percent, $P<0.001$ for both progression-free survival and overall survival) (Fig. 2).

RESPONSE TO CHEMOTHERAPY

The overall response rate was 62 percent in 26 patients with measurable disease after initial surgery (residual tumor or metastasis) (Table 2). In three of nine patients, cerebrospinal fluid was cleared of tumor cells (stage M1) during chemotherapy. No tumor relapse occurred during chemotherapy in patients without measurable disease after surgery. The five-year progression-free survival rate among 29 patients without evidence of disease at the end of chemotherapy was higher than the rate in 14 patients with less than complete remission after chemotherapy (68 ± 9 percent vs. 36 ± 13 percent, $P<0.002$). The overall survival rate was also higher among the patients without evidence of disease than among the patients with less than complete remission (77 ± 8 percent vs. 34 ± 13 percent, $P<0.001$).

RESISTANT DISEASE AND RELAPSES

At the end of the designated chemotherapy, 14 patients had residual disease and received further chemotherapy, radiotherapy, or both. Of these patients, 10 died of progressive disease. Of the remaining four patients, three reached complete remission and one has had stable disease for seven years after further chemotherapy; two patients received additional radiotherapy.

Tumor relapses occurred in 9 of 29 patients with-

out residual disease after chemotherapy. In three patients the tumor relapsed locally, whereas three patients had combined local and stage M2 or M3 relapses and three patients had distant relapses only. After 15.4 months, 75 percent of all patients had no progression or relapse. The relapses that did occur were observed within 2 to 75 months; only two patients had a relapse more than 2 years after initial diagnosis. In total, 16 patients received further treatment at progression or relapse, and 3 patients received no further treatment. Eight of these 16 patients were successfully treated by chemotherapy (2 patients), radiotherapy (2), or both (4, including high-dose chemotherapy in 2 patients). Six of the 16 children (38 percent) are alive after the inclusion of radiotherapy in the salvage therapy.

PROGNOSTIC FACTORS

Multivariate analysis identified histology, stage of metastases, and age as prognostic factors. The risk of an event (relapse or death) was 93 percent lower for children with desmoplastic medulloblastoma than for children with classic medulloblastoma (hazard ratio, 0.07; 95 percent confidence interval, 0.02 to 0.29; $P<0.001$). Patients with macroscopic metastasis (stage M2 or M3) had a 742 percent higher risk of relapse or death (hazard ratio, 8.42; 95 percent confidence interval, 2.36 to 30.03), and children with microscopic dissemination of tumor cells into the cerebrospinal fluid (stage M1) had a 98 percent higher risk of relapse or death (hazard ratio, 1.98; 95 percent confidence interval, 0.47 to 8.36; $P=0.007$ for all metastases) than patients with stage M0 tumors. Children less than two years of age at diagnosis had a risk of relapse or death that was 302 percent higher than that of children between two and three years of age (hazard ratio, 4.02; 95 percent confidence interval, 1.28 to 12.65; $P=0.012$). Postoperative residual tumors, response to chemotherapy, sex, and the use of intraventricular methotrexate (31 patients received cumulative doses of ≥ 48 mg) were not identified as independent prognostic factors.

TOXICITY

There was no major unexpected toxicity from systemic chemotherapy. Myelotoxicity was the most frequently reported side effect; patients required a median of 2 erythrocyte transfusions (range, 0 to 5) during chemotherapy. Admission for neutropenia and fever was common (median, 3 episodes; range, 0 to 6). No treatment-related deaths or lethal infections occurred.

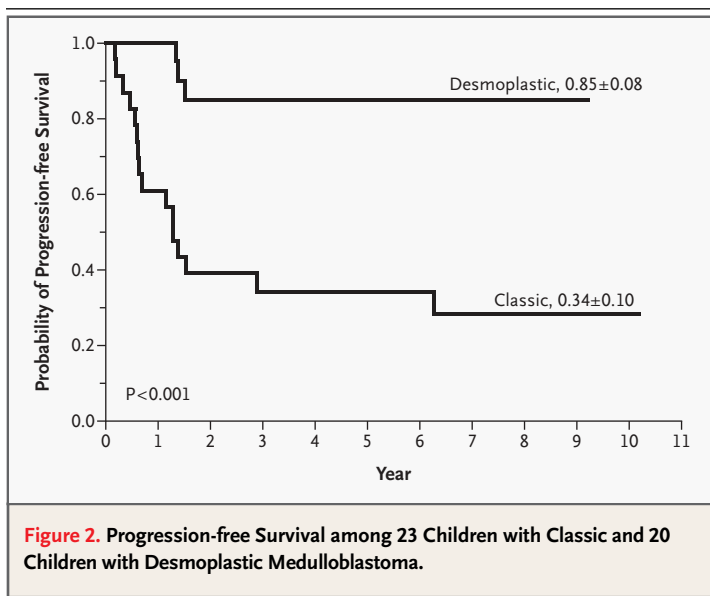


Figure 2. Progression-free Survival among 23 Children with Classic and 20 Children with Desmoplastic Medulloblastoma.

Toxicity data for intraventricular chemotherapy were available from 38 patients. No toxicity was reported for 33 patients, whereas 2 patients had cerebral seizures that were temporally unrelated to the administration of methotrexate. One patient had a cerebrospinal fluid infection with *Staphylococcus epidermidis*. In two of six patients with a ventriculoperitoneal shunt, abdominal ascites developed (no infectious agent was identified); in one child, episodes of ascites did not recur after discontinuation of intraventricular methotrexate, whereas in the other child ascites ceased after removal of the shunt. Methotrexate in the ventricular cerebrospinal fluid was measured in 38 patients 24 hours after each application, and no toxic levels ($>5 \mu\text{mol}$ per liter) were found. In two patients, lumbar cerebrospinal fluid levels of methotrexate were analyzed routinely 24 hours after administration, and levels between 0.21 and 2.2 μmol per liter were documented.

T₂-weighted cranial MRIs of 23 children were available for the evaluation of leukoencephalopathy during and after treatment. Leukoencephalopathy was not detected in four patients. In 19 patients, all without related symptoms, leukoencephalopathy was classified as mild (spotted, circumscribed lesions in 4 children), moderate (patchy lesions in 9 children), or severe (confluent lesions in 6 chil-

dren). The maximal grade of leukoencephalopathy was observed one year after treatment. At further follow-up, the severity of leukoencephalopathy decreased to a lower grade in 10 patients and remained stable in 8 patients. One patient was not available for follow-up. A significant correlation between the grade of leukoencephalopathy and the cumulative dose of intraventricular methotrexate was found (correlation coefficient, 0.53; $P<0.01$), but there was no correlation between the leukoencephalopathy grade and doses of intravenous methotrexate. In six assessable children who had received craniospinal radiotherapy after the application of methotrexate, grade 2 or 3 leukoencephalopathy developed.

NEUROPSYCHOLOGICAL EVALUATION

Detailed neuropsychological follow-up was performed in 14 patients at a median of 4.8 years (range, 3.9 to 8.1) after diagnosis. The mean IQ was significantly lower than in healthy controls within the same age group (T scores, 45 ± 9 vs. 53 ± 8 for the Colored Progressive Matrices test; 38 ± 10 vs. 50 ± 7 for the Kaufmann-Assessment Battery for Children; and 39 ± 8 vs. 52 ± 13 for the Visual-Motor Integration test; $P<0.001$) (Fig. 3). The general intelligence of the children who did not receive radiotherapy

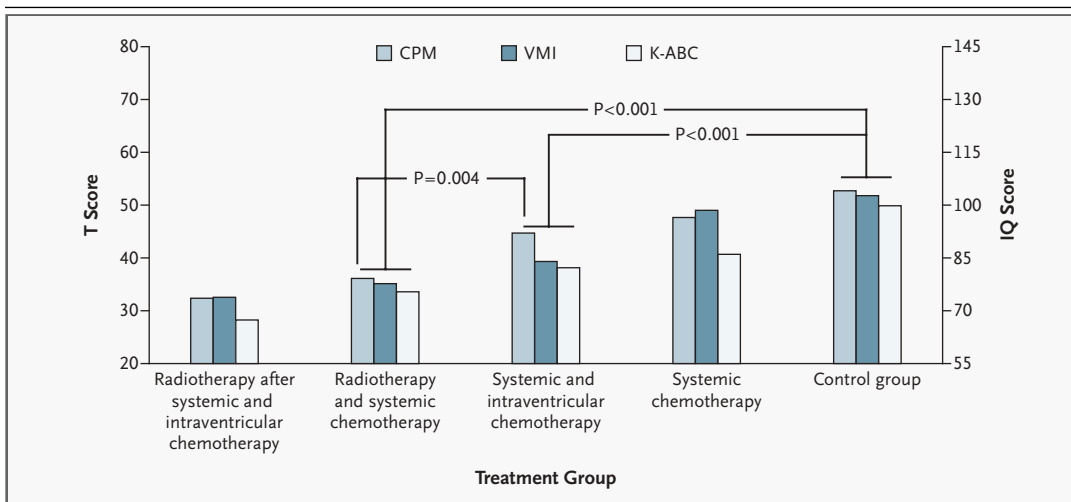


Figure 3. Effect of Treatment on Neurocognitive Functions.

The results of IQ tests are expressed as T scores and IQ points. Neurocognitive deficits in children treated with intraventricular and systemic chemotherapy were less pronounced than the deficits in children receiving radiotherapy. Six children received radiotherapy as salvage therapy after systemic and intraventricular chemotherapy, 11 received systemic chemotherapy and radiotherapy but no intraventricular methotrexate, 14 received systemic chemotherapy and intraventricular methotrexate, and 3 received systemic chemotherapy but no intraventricular methotrexate or radiotherapy. There were 23 children in the control group. CPM denotes Colored Progressive Matrices test, VMI Developmental Test of Visual-Motor Integration, and K-ABC Kaufmann-Assessment Battery for Children.

was significantly higher than the general intelligence of children in a former trial who had received radiotherapy but had not been treated with intraventricular methotrexate¹⁵ (Colored Progressive Matrices test, 45 ± 9 vs. 36 ± 5 ; $P < 0.005$). In addition, there was a trend toward different scores on the Kaufmann-Assessment Battery for Children and the Visual-Motor Integration test between these two groups and a trend toward higher T scores for all applied tests in children receiving systemic chemotherapy only, as compared with children treated with systemic and intraventricular chemotherapy (Fig. 3). Patients treated with radiotherapy after chemotherapy had the lowest IQs (Colored Progressive Matrices test, 32 ± 7 ; Kaufmann-Assessment Battery for Children, 28 ± 11 ; and Visual-Motor Integration test, 33 ± 11).

DISCUSSION

Our study shows that young children with medulloblastoma can enjoy a lengthy remission after treatment with postoperative chemotherapy alone. The estimated survival rates among the 43 patients (five-year progression-free survival, 58 ± 9 percent; overall survival, 66 ± 7 percent) compare favorably with the results of other studies in which combined radiotherapy and chemotherapy or chemotherapy alone was used. The results of our study are especially promising for young children without metastases or postoperative residual tumors (progression-free survival, 82 ± 9 percent; overall survival, 93 ± 6 percent). Likewise, the outcome of children without macroscopic metastases, regardless of the presence or absence of postoperative residual tumors, is encouraging, reaching five-year progression-free and overall survival rates of 68 ± 8 percent and 77 ± 8 percent, respectively.

Radiotherapy was successfully averted in 20 of 31 patients who had no macroscopic metastases. Survival was significantly lower among patients with a stage M2 or M3 tumor (progression-free survival, 33 ± 14 percent; overall survival, 38 ± 15 percent). The identification of stage M1 and macroscopic metastases as strong adverse prognostic factors supports the stratification criteria currently applied in older children.⁵ Other treatments are required for children with macroscopic metastases at diagnosis, but it is noteworthy that three children in this subgroup have remained in remission for more than five years without requiring radiotherapy. Although the presence of a postoperative residual tumor was not

shown statistically to be an independent adverse prognostic factor, we believe that this presentation justifies maximal surgery at diagnosis. Given the small size of this study, we regard multivariate analysis as explorative, and P values as descriptive.

Overall response rates in our study (62 percent) compare favorably with rates reported previously.^{12,20} Notably, no tumor progression was observed during chemotherapy in the 31 children without initial macroscopic metastases. In contrast to other studies in which the risk of progression along the neuroaxis increased with the duration of chemotherapy,^{21,22} our study involved chemotherapy that had a favorable safety profile.

Survival among patients in our pilot trial with delayed radiotherapy was poorer than among patients in the present trial, and no patient in the pilot trial received successful salvage therapy after relapse (overall survival rate, 71 percent and 45 percent for nonmetastatic disease without and with postoperative residual tumor, respectively, and 0 percent for patients with initial metastases). The psychological outcome and the school performance were worse in the survivors who received radiotherapy than in the children in the present trial. However, the two regimens differed not only in the use of radiotherapy and intraventricular methotrexate but also in the systemic chemotherapy (procarbazine, ifosfamide, and cytarabine were used in the pilot trial but not in the present study).

Desmoplastic medulloblastoma in older children is associated with a better survival,²³ but the relevance of desmoplasia in young children is unclear. In our study, the 20 children with desmoplastic histology had a better outcome than the 23 with classical medulloblastoma (progression-free survival, 85 ± 8 percent vs. 34 ± 10 percent; overall survival, 95 ± 5 percent vs. 41 ± 11 percent; $P < 0.001$), and desmoplastic histology was identified as an independent favorable prognostic factor. These data suggest that the stratification of risk groups may be improved by consideration of desmoplasia in young children with medulloblastoma. In our study, an age of two years or less at diagnosis was a statistically significant adverse risk factor as compared with an age between two and three years.

Neurotoxicity after the administration of intrathecal methotrexate has been related to direct toxic effects and interference with metabolic pathways in the brain,²⁴ and cases of inadvertent intraparenchymal instillation of methotrexate have been described.²⁵ Therefore, toxicity and the neuropsychological

logical outcome were of special interest in our study. No child had symptoms of methotrexate-induced neurotoxicity. Toxic methotrexate levels in cerebrospinal fluid were not reported. Chemical peritonitis developed during chemotherapy in two of six children with a ventriculoperitoneal shunt. Thus, intraventricular methotrexate cannot be recommended for children with a ventriculoperitoneal shunt lacking a device for transient shunt occlusion.

Not unexpectedly, moderate to severe leukoencephalopathy was found in 15 of 23 patients. A significant correlation was found between the grade of leukoencephalopathy and the cumulative dose of intraventricular methotrexate, suggesting a dose-dependent effect of methotrexate on leukoencephalopathy. Leukoencephalopathy did not cause symptoms and was a transient phenomenon in 10 children.

After treatment, the results of all IQ tests (the Colored Progressive Matrices test, the Kaufmann-Assessment Battery for Children, and the Developmental Test of Visual-Motor Integration) were significantly lower than the results of the tests in healthy controls of the same age group, indicating that the disease itself, surgery, and chemotherapy have a negative effect on neurocognitive functions. However, the results of the Colored Progressive Matrices test in children treated with chemotherapy alone was significantly higher than the results of the test in patients in our previous trial who received radiotherapy but did not receive intraventricular methotrexate (45 ± 9 vs. 36 ± 5 , $P < 0.005$).

In conclusion, this study shows that lengthy remissions can be obtained in young children with medulloblastoma by intensive postoperative che-

motherapy. Results are especially promising for patients without initial metastases, in whom radiotherapy should be reserved for salvage strategies at relapse.

Supported by grants from the German Cancer Aid (Deutsche Krebshilfe 70-1667), the German Children's Cancer Foundation (Deutsche Kinderkrebsstiftung DKS 2001.03 and DKS 2004.03), and the Association of Parents for Children with Cancer, Würzburg, Germany. Miss Emser is supported by the German Children's Cancer Foundation, and Dr. Pietsch is supported by the German Cancer Foundation, by the German Ministry of Education and Research, and by a Bonfor Grant of the University of Bonn.

This article is dedicated to the memory of Joachim Kuehl, who died in 2003. The pediatric neuro-oncology community will preserve his memory.

We are indebted to the following participating pediatric centers, in the name of the German Pediatric Brain Tumor Study Group of the German Society of Pediatric Oncology and Hematology: University of Aachen, Aachen (R. Mertens); University of Berlin/Charité, Berlin (G. Henze); University of Bonn, Bonn (U. Bode); Prof.-Hess-Kinderklinik, Bremen (J. Spaar); University of Düsseldorf, Düsseldorf (U. Goebel); University of Erlangen, Erlangen (J. Beck); University of Essen, Essen (W. Havers); University of Freiburg, Freiburg (C. Niemeyer); Klinikum Fulda, Fulda (H. Töllner); University of Giessen, Giessen (A. Reiter); University of Göttingen, Göttingen (M. Lakomek); University of Hamburg, Hamburg (G. Janka-Schaup); University of Heidelberg, Heidelberg (B. Selle); University of Homburg/Saar, Homburg/Saar (N. Graf); Klinikum Karlsruhe, Karlsruhe (W. Dupuis); University of Kiel, Kiel (M. Suttrop); Klinikum Koblenz, Koblenz (M. Rister); University of Köln, Köln (F. Berthold); University of Lübeck, Lübeck (P. Bucsky); Klinikum Mannheim, Mannheim (O. Sauer); University of Marburg, Marburg (C. Eschenbach); Kinderklinik München-Schwabing, Munich (S. Mueller-Weihrich); University of Munich, Munich (J. Haas); University of Münster, Münster (H. Juergens); Klinik St. Hedwig Regensburg, Regensburg (M. Helmig); DRK-Kinderklinik Siegen, Siegen (F.-J. Göbel); Olga-Hospital, Stuttgart (J. Treuner); Krankenhaus Trier, Trier (W. Rauh); University of Tübingen, Tübingen (D. Niethammer); University of Würzburg, Würzburg (J. Kuehl); and Klinikum Wuppertal, Wuppertal (B. Dohrn) — all in Germany. We are also indebted to W. Roggenendorf (Institute of Neuropathology, University of Würzburg, Würzburg, Germany) and the pathologists of all the participating centers for their cooperation; to Julia Becker (HIT data center, Würzburg) for excellent data management; and to K. Kerksiek and P.-G. Schlegel for assistance with preparation of the manuscript.

APPENDIX

In addition to the authors, the following investigators participated in the German Pediatric Brain Tumor Study Group Trial (HIT-SKK'92) as members of the study committee: *Germany* — J. Beck, University of Erlangen, Erlangen; F. Berthold, University of Koeln, Koeln; A. Gnekow, Klinikum Krankenhauszweckverbandes Augsburg, Augsburg; U. Goebel, University of Düsseldorf, Düsseldorf; P. Gutjahr and P. Kaatsch, University of Mainz, Mainz; W. Havers, University of Essen, Essen; G. Henze, University of Berlin, Berlin; M. Lakomek, University of Goettingen, Goettingen; E. Maas, Olga-Hospital, Stuttgart; U. Mittler, University of Magdeburg, Magdeburg; S. Mueller-Weihrich, Kinderklinik Muenchen-Schwabing, Munich; D. Niethammer, University of Tübingen, Tübingen; D. Rating, University of Heidelberg, Heidelberg; H.-J. Riehm and P. Weinel, University of Hannover, Hannover; J. Spaar, Prof.-Hess-Kinderklinik, Bremen; O. Wiestler, University of Bonn, Bonn; K. Winkler, University of Hamburg, Hamburg; *Austria* — I. Slave, University of Vienna, Vienna; C. Urban, University of Graz, Graz.

REFERENCES

1. Kaatsch P, Rickert CH, Kuehl J, Schuez J, Michaelis J. Population-based epidemiologic data on brain tumors in German children. *Cancer* 2001;92:3155-64.
2. Kellie SJ. Chemotherapy of central nervous system tumours in infants. *Childs Nerv Syst* 1999;15:592-612.
3. Evans AE, Jenkin RD, Sposto R, et al. The treatment of medulloblastoma: results of a prospective randomized trial of radiation therapy with and without CCNU, vincristine, and prednisone. *J Neurosurg* 1990;72:572-82.
4. Zeltzer PM, Boyett JM, Finlay JL, et al. Metastasis stage, adjuvant treatment, and residual tumor are prognostic factors for medulloblastoma in children: conclusions from the Children's Cancer Group 921 randomized phase III study. *J Clin Oncol* 1999;17:832-45.
5. Packer RJ, Rood BR, MacDonald TJ.

- Medulloblastoma: present concepts of stratification into risk groups. *Pediatr Neurosurg* 2003;39:60-7.
6. Mulhern RK, Horowitz ME, Kovnar EH, Langston J, Sanford RA, Kun LE. Neurodevelopmental status of infants and young children treated for brain tumors with preirradiation chemotherapy. *J Clin Oncol* 1989;7:1660-6.
 7. Jenkin D, Danjoux C, Greenberg M. Subsequent quality of life for children irradiated for a brain tumor before age four years. *Med Pediatr Oncol* 1998;31:506-11.
 8. Kiltie AE, Lashford LS, Gattamaneni HR. Survival and late effects in medulloblastoma patients treated with craniospinal irradiation under three years old. *Med Pediatr Oncol* 1997;28:348-54.
 9. Hoppe-Hirsch E, Brunet L, Laroussinie F, et al. Intellectual outcome in children with malignant tumors of the posterior fossa: influence of the field of irradiation and quality of surgery. *Childs Nerv Syst* 1995;11:340-6.
 10. Palmer SL, Goloubeva O, Reddick WE, et al. Patterns of intellectual development among survivors of pediatric medulloblastoma: a longitudinal analysis. *J Clin Oncol* 2001;19:2302-8.
 11. White L, Kellie S, Gray E, et al. Postoperative chemotherapy in children less than 4 years of age with malignant brain tumors: promising initial response to a VETOPEC-based regimen. *J Pediatr Hematol Oncol* 1998;20:125-30.
 12. Ater JL, van Eys J, Woo SY, Moore B III, Copeland DR, Bruner J. MOPP chemotherapy without irradiation as primary postsurgical therapy for brain tumors in infants and young children. *J Neurooncol* 1997;32:243-52.
 13. Baram TZ, van Eys J, Dowell RE, Cangir A, Pack B, Bruner JM. Survival and neurologic outcome of infants with medulloblastoma treated with surgery and MOPP chemotherapy: a preliminary report. *Cancer* 1987;60:173-7.
 14. White L, Johnston H, Jones R, et al. Postoperative chemotherapy without radiation in young children with malignant non-astrocytic brain tumours. *Cancer Chemother Pharmacol* 1993;32:403-6.
 15. Kuehl J, Beck J, Bode U, et al. Delayed radiation therapy after postoperative chemotherapy in children less than 3 years of age with medulloblastoma: results of the trial HIT-SKK'87 and preliminary results of the pilot trial HIT-SKK'92. *Med Pediatr Oncol* 1995;25:Suppl:250. abstract.
 16. Ruggiero A, Conter V, Milani M, et al. Intrathecal chemotherapy with antineoplastic agents in children. *Paediatr Drugs* 2001;3:237-46.
 17. Riva D, Giorgi C, Nichelli F, et al. Intrathecal methotrexate affects cognitive function in children with medulloblastoma. *Neurology* 2002;59:48-53.
 18. Chang CH, Housepian EM, Herbert C Jr. An operative staging system and a megavoltage radiotherapeutic technic for cerebellar medulloblastomas. *Radiology* 1969;93:1351-9.
 19. Fazekas F. Magnetic resonance signal abnormalities in asymptomatic individuals: their incidence and functional correlates. *Eur Neurol* 1989;29:164-8.
 20. Duffner PK, Horowitz ME, Krischer JP, et al. Postoperative chemotherapy and delayed radiation in children less than three years of age with malignant brain tumors. *N Engl J Med* 1993;328:1725-31.
 21. Attard-Montalto S, Plowman N, Breatnach F, Saha V, Eden OB. Is there a danger in delaying radiotherapy in childhood medulloblastoma? *Br J Radiol* 1993;66:807-13.
 22. Hartsell WF, Gajjar A, Heideman R, et al. Patterns of failure in children with medulloblastoma: effects of preirradiation chemotherapy. *Int J Radiat Oncol Biol Phys* 1997;39:15-24.
 23. Eberhart CG, Kepner JL, Goldthwaite PT, et al. Histopathologic grading of medulloblastomas: a Pediatric Oncology Group study. *Cancer* 2002;94:552-60.
 24. Vezmar S, Becker A, Bode U, Jaehde U. Biochemical and clinical aspects of methotrexate neurotoxicity. *Chemotherapy* 2003;49:92-104.
 25. Gottschling S, Reinhard H, Meyer S, Krenn T, Graf N, Strowitzki M. Severe encephalopathy caused by intraparenchymal methotrexate instillation due to the design of the catheter. *Med Pediatr Oncol* 2003;41:491-2.

Copyright © 2005 Massachusetts Medical Society.

**RECEIVE THE JOURNAL'S TABLE OF CONTENTS
EACH WEEK BY E-MAIL**

To receive the table of contents of the
New England Journal of Medicine by e-mail
every Wednesday evening and access our archives
of research articles (>6 months old),
you can sign up through our Web site at:
www.nejm.org