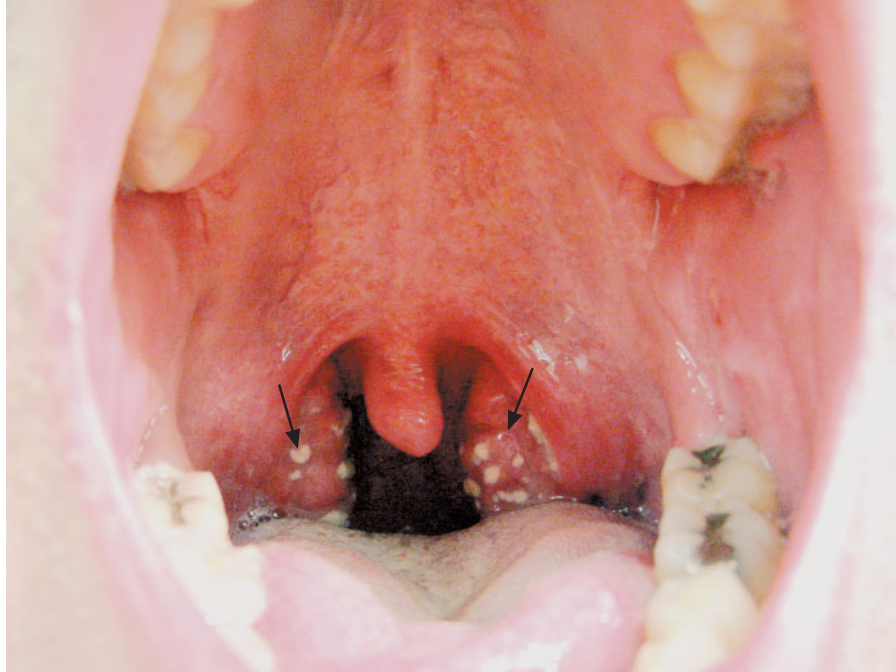


IMAGES IN CLINICAL MEDICINE

## Streptococcal Pharyngitis



Shilpa Nimishikavi, M.D.  
Latha Stead, M.D.

Mayo Clinic  
Rochester, MN 55905

A 26-YEAR-OLD MAN PRESENTED TO THE EMERGENCY DEPARTMENT with a two-day history of a sore throat. He was unable to eat solids because of pain and swelling but was tolerating liquids. He was afebrile but had taken 800 mg of ibuprofen one hour before arrival. On physical examination, a white exudate was seen on the tonsils (arrows). The patient was treated with 1.2 million units of penicillin G benzathine intramuscularly and given a benzocaine spray for topical analgesia. The results of a throat culture confirmed the diagnosis of streptococcal pharyngitis.

Streptococcal pharyngitis is caused by group A  $\beta$ -hemolytic streptococci and most often affects persons situated in close quarters. Common symptoms include sore throat, pain on swallowing, and fever. The classic finding on physical examination is the presence of white exudates on swollen tonsils, as seen in the image. It is important to treat this self-limited illness in order to prevent rheumatic fever.

Copyright © 2005 Massachusetts Medical Society.