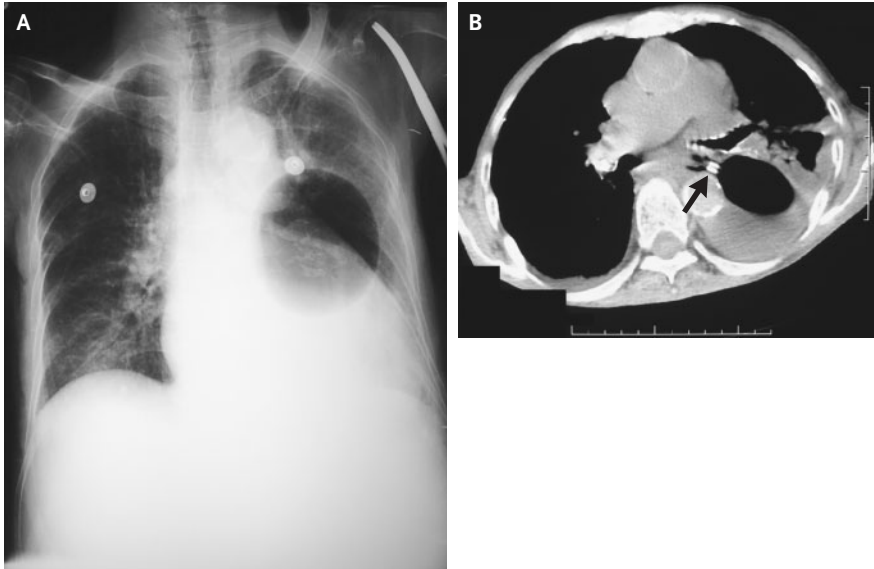


IMAGES IN CLINICAL MEDICINE

## Malposition of a Sengstaken–Blakemore Tube



**A**N 86-YEAR-OLD WOMAN HAD A HISTORY OF CIRRHOSIS ASSOCIATED with chronic hepatitis B infection lasting more than 16 years; she had had five episodes of esophageal variceal bleeding that had required placement of a Sengstaken–Blakemore tube for tamponade and had undergone subsequent sclerotherapy. The patient presented to the emergency department with a new episode of hematemesis, and a Sengstaken–Blakemore tube was placed. Subsequently, the patient had pain in the left chest area, and chest radiography showed a malpositioned gastric balloon (Panel A). Computed tomography of the chest showed that the tube had penetrated the esophageal wall (arrow, Panel B), with the gastric balloon visible in the left pleural cavity. Emergency surgical repair was suggested but declined by the patient and her family. Left empyema developed, and the patient died of septic shock two weeks later. Complications of the implantation of a Sengstaken–Blakemore tube are commonly associated with the inflation of the gastric balloon outside the stomach.

Copyright © 2005 Massachusetts Medical Society.

Jung-Yien Chien, M.D.

National Taiwan University Hospital,  
Yun-Lin Branch  
Douliu 640, Taiwan

Chong-Jen Yu, M.D., Ph.D.

National Taiwan University Hospital  
Taipei 100, Taiwan