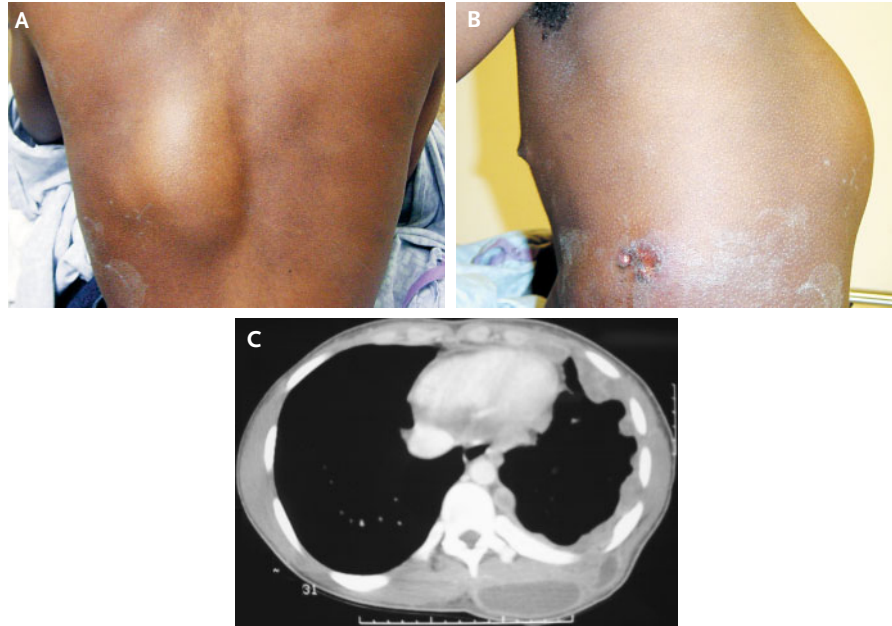


IMAGES IN CLINICAL MEDICINE

Tuberculosis Empyema Necessitatis



Kongkrit Chaiyasate, M.D.
John Hramiec, M.D.

Providence Hospital and Medical Centers
Southfield, MI 48075

AN 18-YEAR-OLD MAN WITH NO CLINICALLY SIGNIFICANT MEDICAL HISTORY presented with a six-month history of an increasing mass on the left side of his back (Panel A). About three days before seeking medical attention, the patient had noticed serous drainage from a sore on the left lateral wall of his chest (Panel B). Chest radiography showed multiple left-sided pleural nodules with a consolidation in the left lower lobe. Computed tomography of the chest showed numerous pleural nodules encasing the left lung and a large collection of fluid in the musculature of the left back (Panel C), which was consistent with empyema necessitatis, in which pus can escape toward the chest wall. Although the results of the pleural biopsy were culture-negative, the pleural-fluid culture was positive for *Mycobacterium tuberculosis*. The test for infection with the human immunodeficiency virus was negative. Since the mycobacteria were fully susceptible to all antimycobacterial agents, the patient began treatment with a standard antituberculosis regimen, and his condition slowly improved.

Copyright © 2005 Massachusetts Medical Society.