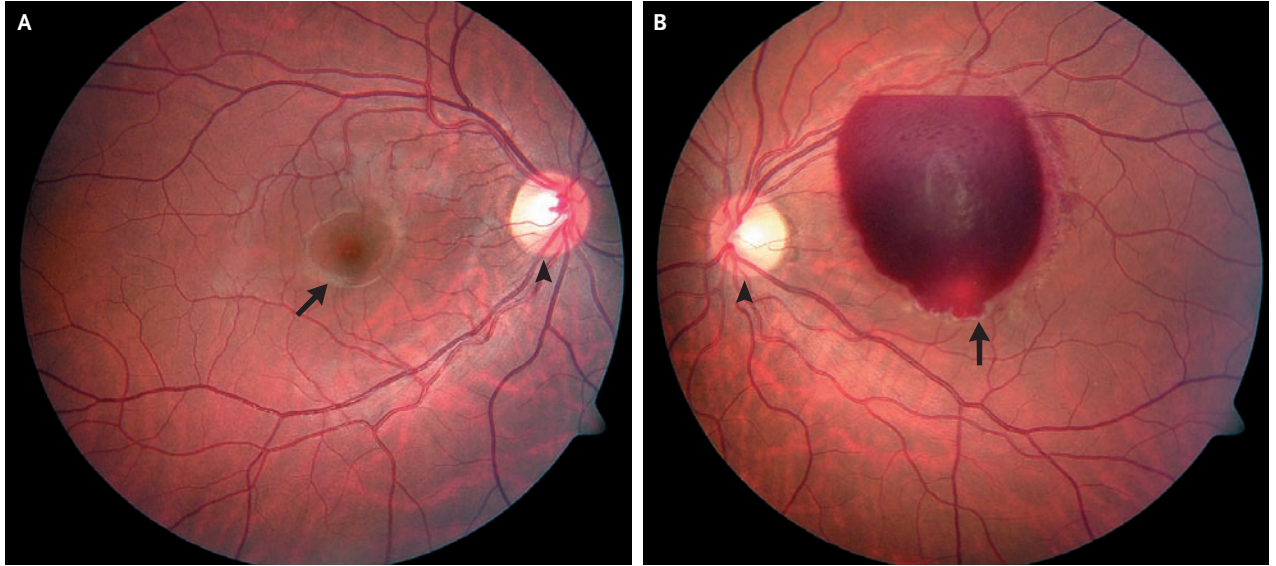


IMAGES IN CLINICAL MEDICINE

Macular Hemorrhage from Bungee Jumping



A 25-YEAR-OLD WOMAN WITH NO CLINICALLY SIGNIFICANT MEDICAL HISTORY and with normal coagulation and hematologic studies went bungee jumping from a vertical height of 150 ft (45.7 m). Immediately afterward, she noticed a substantial decrease in vision in her left eye, with a large central scotoma; no other symptoms were noted and there was no pain. On examination, the patient's right eye was found to have a normal disc and vessels (Panel A, arrowhead) and normal fovea and macula (Panel A, arrow). Examination of the left eye showed a normal disc and vessels (Panel B, arrowhead), but the foveal and macular architecture was obscured by a large macular hemorrhage just below the level of the internal limiting membrane (Panel B, arrow). Vision was 20/400 in the left eye when the patient used peripheral scanning and 20/20 in the right eye. The patient had a form of Valsalva retinopathy due to increased venous pressure in the upper body, brought about by sudden deceleration in the head-down position (such as occurs during bungee jumping). She underwent surgery with evacuation of the blood in the left eye. Visual acuity in the left eye 1 week later was 20/25 and has remained stable.

Copyright © 2007 Massachusetts Medical Society.

Atul K. Jain, M.D.
Michael Gaynon, M.D.

Stanford University
Stanford, CA 94305-5308
atuljain@stanford.edu