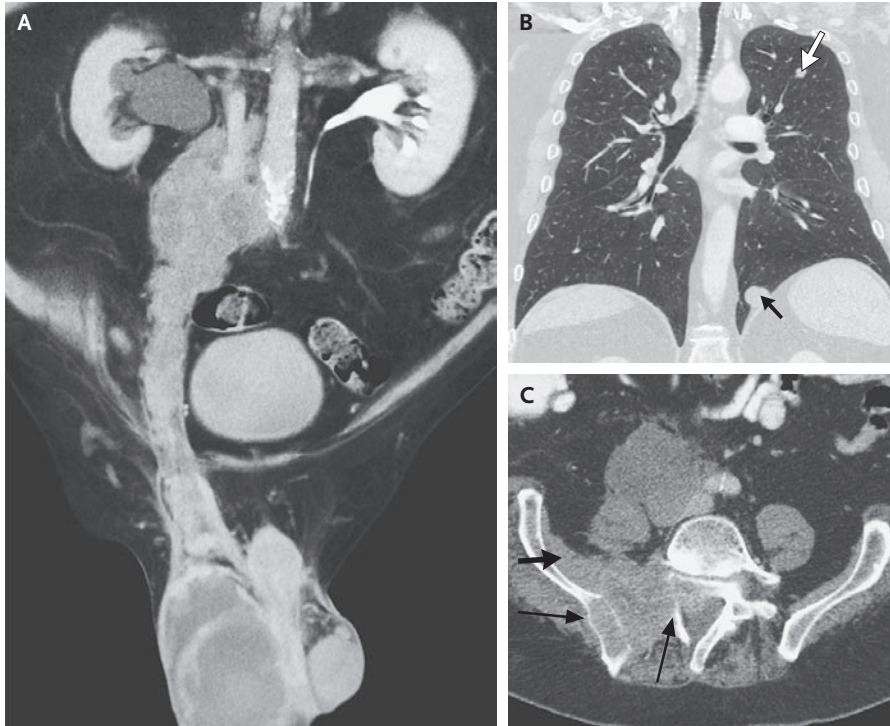


IMAGES IN CLINICAL MEDICINE

Metastatic Germ-Cell Cancer



A 60-YEAR-OLD MAN PRESENTED WITH PROGRESSIVE SWELLING OF THE right side of the scrotum. He reported no history of trauma to this area and no sexually transmitted infections. The alpha-fetoprotein level was elevated at 3100 μg per liter (normal value, <8), and the serum level of the beta subunit of human chorionic gonadotropin was less than 1 IU per liter. Multidetector computed tomography with multiplanar reformation (Panel A) showed a large testicular tumor with lymphangitic spread along the testicular vessels to the associated draining lymph nodes below the renal hilus. Right-sided hydronephrosis is present because of compression of the ureter by the lymphatic metastases. Imaging also showed lung metastases (Panel B, arrows) and ileosacral osseous metastases (Panel C, long arrows) with infiltration of the iliac muscle (Panel C, short arrow) and the sacral spinal channel. Right-sided radical inguinal orchiectomy was performed, and histologic examination confirmed the diagnosis of advanced nonseminomatous germ-cell cancer. The patient subsequently received chemotherapy, which was complicated by fulminant septic shock in the setting of aplasia, which led to the patient's death from multiorgan failure. These images show classic lymphatic and hematogenous metastatic pathways of advanced testicular cancer.

Copyright © 2007 Massachusetts Medical Society.

Jan Menke, M.D.
Eckhardt Grabbe, M.D.
University Hospital
37075 Göttingen, Germany